

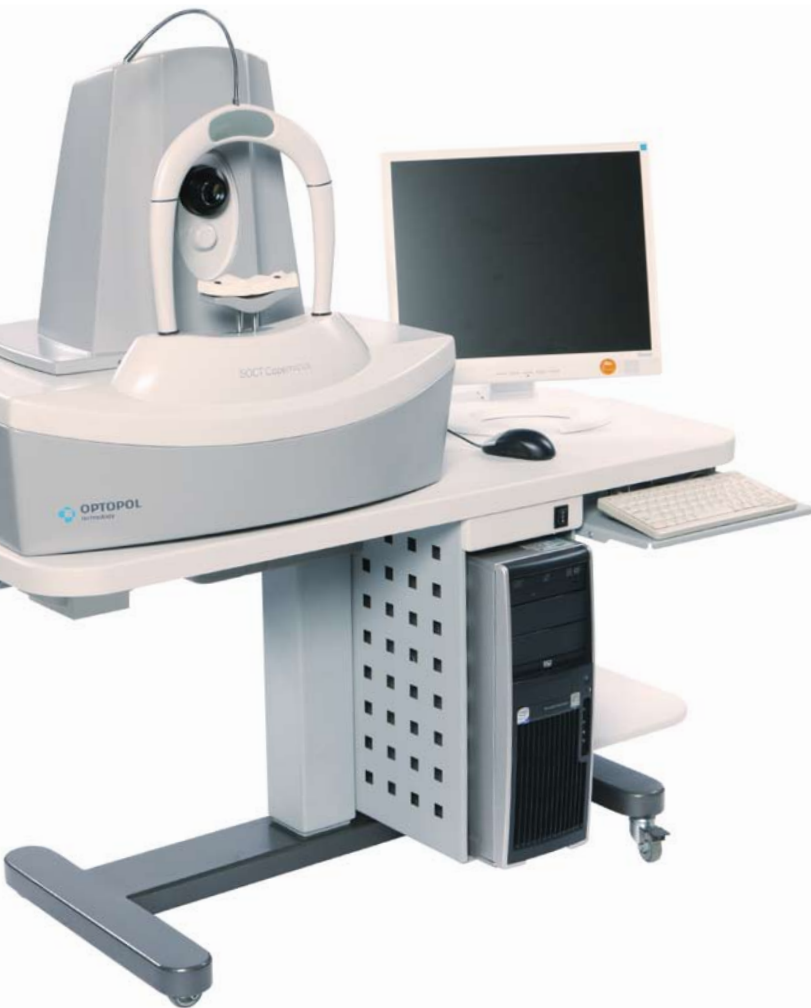

SOCT Copernicus



SOCT Copernicus

Spectral Optical Coherence
Tomography System
Future in ophthalmic diagnosis



Laboratory and assembly of SOCT Copernicus

Every device is carefully assembled and thoroughly re-checked in order to make sure that the received product is of the highest quality.

At Optopol we understand the importance of expanding new possibilities in ophthalmologic diagnosis. That is why a team of qualified professionals constantly work to develop new technologies that will increase the possibilities of our already advanced devices, like the SOCT Copernicus.

Optical tomography is a very modern, non-invasive technology of cross-sectional imaging of tissue (eg. eye retina), in which light is diffused on particular layers of the examined tissue.

By implementing new solutions such as spectral tomography the SOCT Copernicus is the most advanced OCT system in its class.

The SOCT Copernicus uses cutting edge technology which is constantly developed. Every single software and hardware advancement is made available as an upgrade to an already purchased Copernicus. This means that as the SOCT's possibilities evolve no Copernicus will be left behind*.

In comparison with other devices of this type (ie. So called time domain), images acquired with the SOCT Copernicus have much higher resolution and examining may last around 50 times shorter.

Receiving three dimensional images is simple thanks to the short time of making B-scans.

In addition to precise OCT images and optic nerve diagnosis the SOCT Copernicus provides analytical support to the generated images, including maps and graphs presenting Retina and RNFL thickness and RPE deformations.

The SOCT Copernicus is the first and longest commercially available SOCT device. Meaning that it has already gained unprecedented support from over 100 clinical users from around the globe.

Our experience and expertise means that we will keep on expanding new possibilities in ophthalmologic diagnosis.

* Please contact your local distributor for further details.

Available product functions:

- Glaucoma analysis module:
 - ONH data
 - DDLS
 - RNFL analysis
 - automatic disc and cup detection
 - disc, cup, rim area
 - cup/disc area ratio
 - disc, cup, rim volume
 - cup/disc volume ratio
 - mean and max cup depth
 - disc, cup diameter
- Retina Analysis Module
- IS/OS-RPE thickness map
- 3D module

SOCT Copernicus Glaucoma Module

A Powerful Predictor of Change

- Validated by Ophthalmologists to predict structural change
- Optic disc analysis outperforms expert interpretation
- Large normative database
- Asymmetrical analysis
- Network ready
- DICOM connectivity.

The SOCT Copernicus Glaucoma Module is an essential tool for the detection and management of Glaucoma. Essentially, the tool allows detection on pupillary defect and tracks progression with time. The essential components of the Glaucoma Module are:

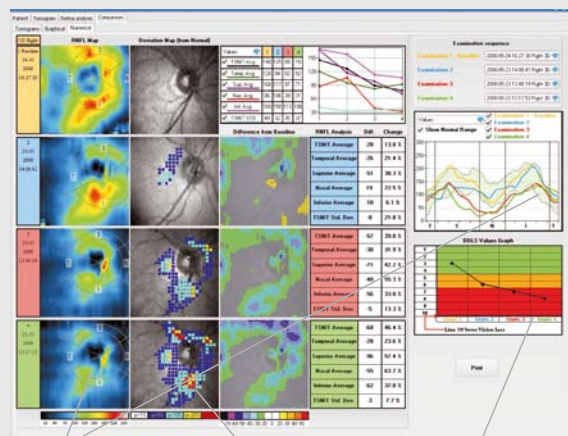
1. Disk Damage Likelihood Scale (DDLS): The DDLS is a new way to analyze the optic nerve. Instead of a cup/disc (c/d) ratio, a rim/disc (r/d) ratio and the nerve size is measured. This methodology is superior than any other reporting measure for two reasons:

- DDLS eliminates the effects of disc size, which is so variable in people.
- DDLS measure provides more weightage to the rim, which is the actual part that is damaged in Glaucoma.

2. Asymmetry analysis: Asymmetry analysis correctly identifies patients with glaucomatous field loss and shows abnormalities in many patients considered at high risk for glaucoma who still have normal fields. Asymmetry analysis is also able to identify objectively the extent of glaucomatous damage and detects changes before subjective field loss occurs.

3. Symmetrical progressions analysis: Glaucoma module allows complete and detailed progression analysis of the RNFL thickness, comparison to the normal population, DDLS scale and difference from baseline plots to highlight progression and/or comparison of disc scans at various stages of time.

Symmetrical Analysis

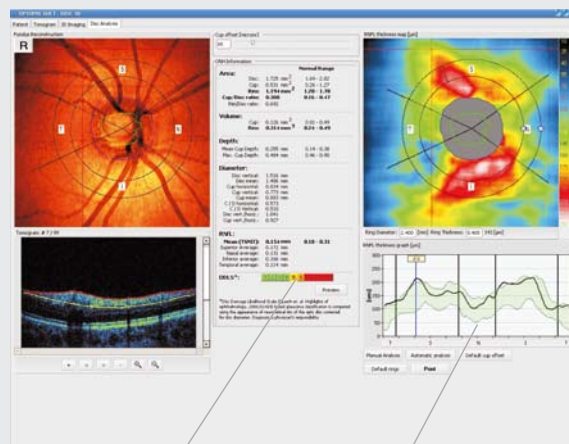


RNFL thickness map shows significant differences with time

Deviation from normal is seen to increase with time.

DDLS graph showing damage progression.

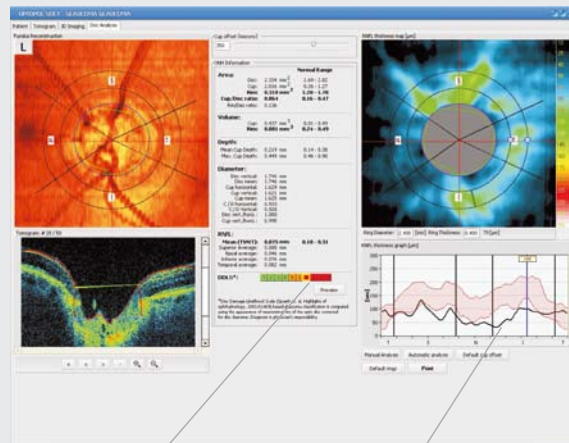
Healthy Disc



DDLS scale shows "caution" rating.

RNFL trend follows normative curve.

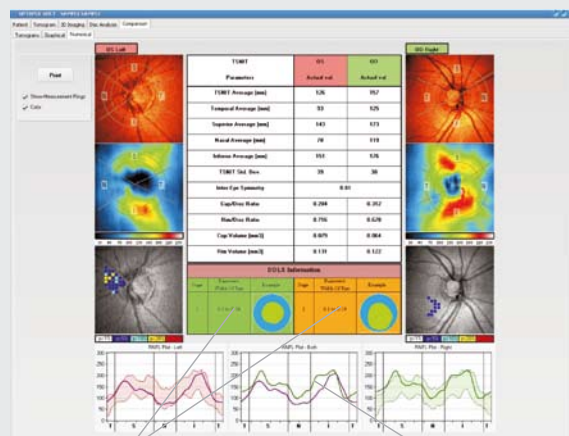
Glaucomatous Disc



DDLS scale shows high damage.

RNFL thickness at the rim is below normal.

Asymmetrical Analysis

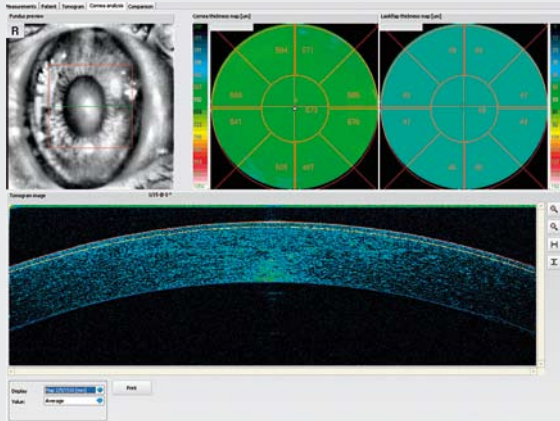


Differences in the value of DDLS reconfirm the early stages of defect.

A comparison of functionally and visually healthy left and right eye showing early signs of papillary defect.

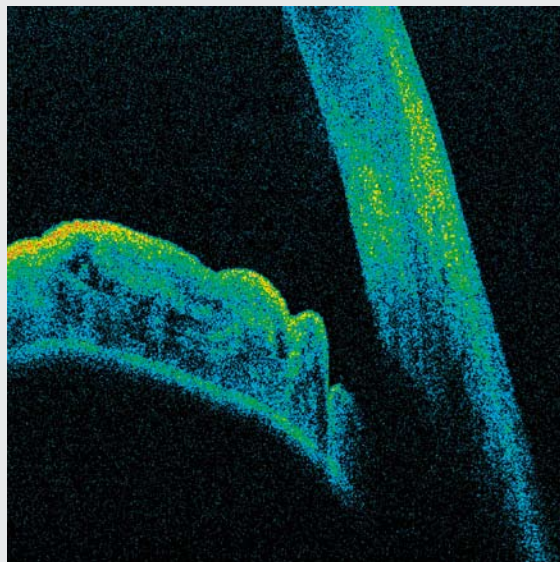
Anterior Segment Module

The anterior segment module allows cornea and anterior imaging with a resolution of 3 micron.

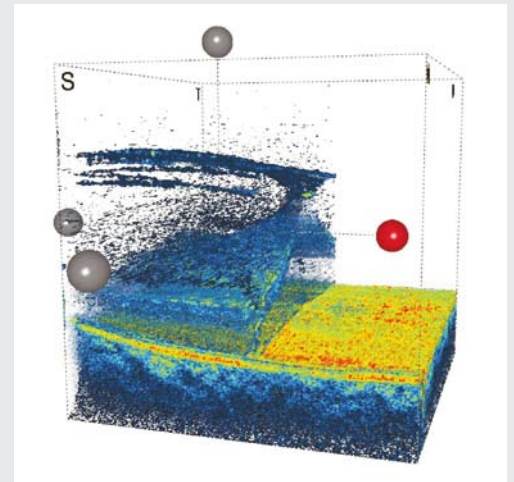


SOCT Copernicus software allows:

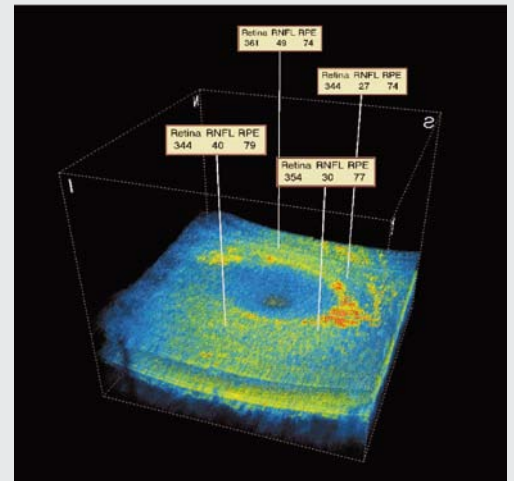
1. Pachymetry map.
2. Epithelium thickness measurement.
3. LASIK Flap thickness measurement.
4. Anterior angle measurement.




3D and Fovea



The new advanced 3D module allows visualization of the 3D reconstruction. Peeling facilitates localization and review of the pathology for detailed analysis.



Thickness of the retina, RNFL and RPE can be highlighted for any spot on the 3D picture - enabling quick and easy study of the structures.



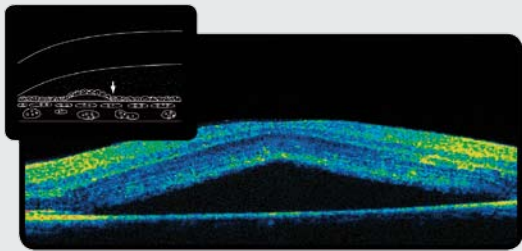
Vitreomacular tractions can be visualized, highlighted and removed for easy patient understanding

SOCT Copernicus

Technical Data

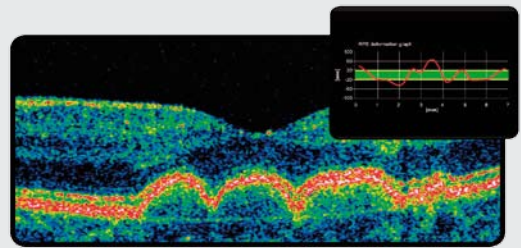
Technology	Spectral domain OCT
Measurement mode	Single B-scan, 3D mode, Asterisk, Animation scan, Circle, user defined scan parameters
Fixation	Internal and external fixations
Light source wavelength	830 nm, 50 nm half bandwidth
Axial resolution	6 μm
Transversal resolution	12 - 18 μm
Axial scanning window	2 mm
Examination speed	25'000 A-scans per second
Maximum number of A-scans per B-scans	10'500
Minimum pupil diameter for measurement	3 mm
Display	<ul style="list-style-type: none">- Single B-scan with colour mask- 3D retina imaging (zooming, rotating, sectioning, surface reconstruction)- Circular Disc Scan- Retina thickness analysis module- Topographic maps of retina thickness- RNFL thickness analysis- ONH DATA- Creating AVI animations of retina cross-sections- RNFL topographic maps- RNFL thickness graph for nerve head neighbouring area- RPE analysis module- RPE deformation maps
Printout	User customized, predefinable styles
Power supply	230V 50 Hz/115V 60 Hz
All head movements motorized (using electrical actuators) and controlled from the computer screen	
Direct fundus preview during scanning	
Image enhancement module	

SOCT Copernicus Image



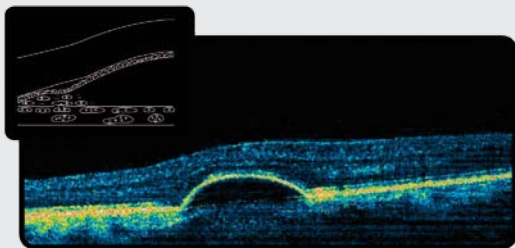
Central Serious Chorioretinopathy

SOCT Copernicus image reveals significant amount of fluid collected under the central area of retina. The sensory part of retina is not fully damaged but elevated by the pool of fluid.



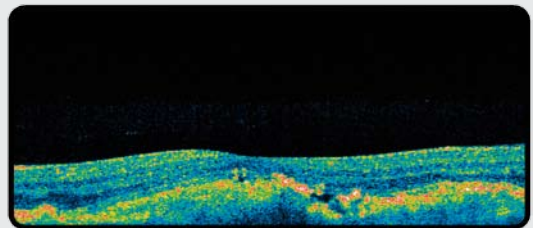
Drusen

RPE deformation graph reveals deformation beyond normative data (marked by green).



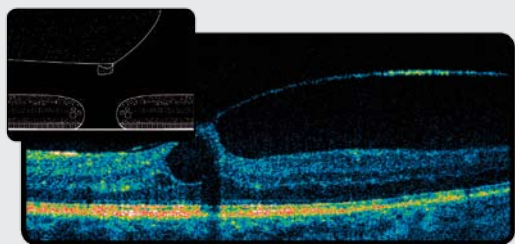
Pigment Epithelial Detachment

Small amount of fluid under neurosensory retina is clearly visible on the SOCT Copernicus tomographic image.



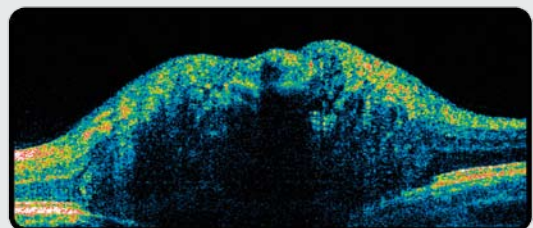
Wet AMD

Age Related macular Degeneration can be easily diagnosed thanks to sharp images obtained using SOCT Copernicus.



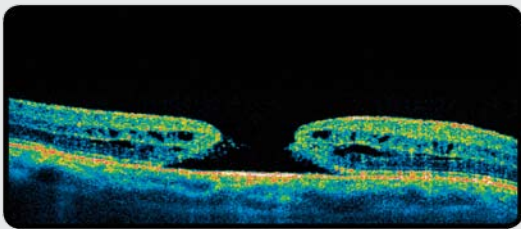
Tractions

Tractions can be easily identified on SOCT Copernicus images as highly reflective "wires" pulling retina particles in cases of macular holes or macular detachments.



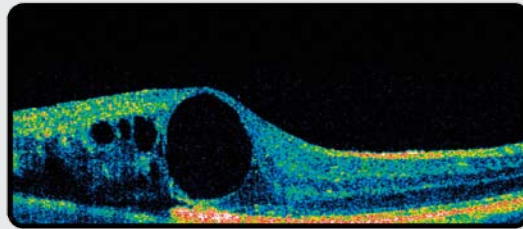
Optical nerve head drusen

Optic Nerve Head Drusen can be easily imaged using SOCT Copernicus.



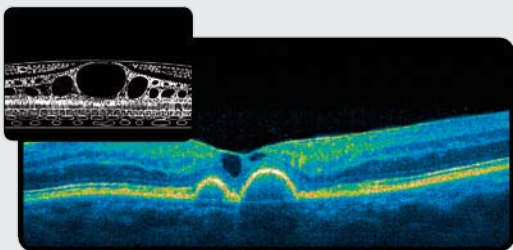
Macular hole

SOCT Copernicus macular hole image shows abnormal opening in neurosensory retina. Intraretinal cystoid changes are also clearly visible on the image.



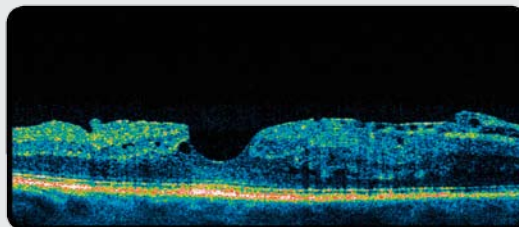
BRVO (Branch retinal vein occlusion)

SOCT Copernicus image shows damages to retina caused by blocked retinal veins.



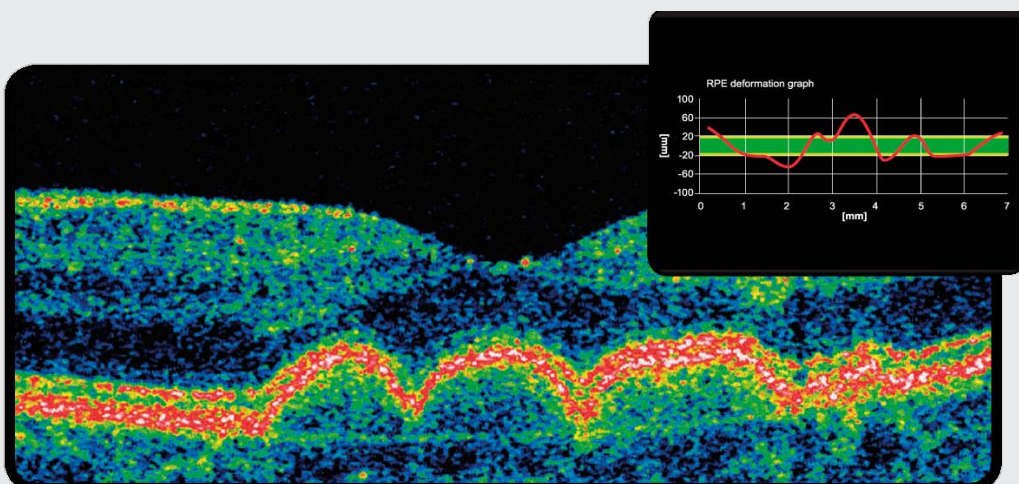
Macular edema with drusen and traction

Image of macular edema taken using SOCT Copernicus clearly shows intraretinal cystic areas and large drusen.



Epiretinal membrane with lamellar macula hole

Image of Epiretinal Membrane (ERM) depicting highly reflective membrane anterior to the retina with macular pucker. ERM has also resulted into the formation of a lamellar macular hole.





OPTOPOL Technology S.A.
ul. Żabia 42, 42-400 Zawiercie, POLAND

Tel/Fax: +48 32 6709173
info@optopol.com.pl

www.optopol.com

Local Distributor: